

High-density optical mapping of the human somatosensory cortex to vibrotactile stimulation

Stefan P. Koch¹, Jan Mehnert^{1,2}, Christoph Schmitz^{1,3}, Susanne Holtze¹, Arno Villringer^{1,2,4}, Hellmuth Obrig^{1,2,5}



¹Berlin Neuroimaging Center, Charité Berlin, Germany/ ²Max-Planck Institute for Human Cognitive and Brain Science Leipzig, Germany/ ³NIRx Medizintechnik GmbH, Berlin, Germany/ ⁴Berlin School of Mind and Brain, Humboldt-University/ ⁵Day Clinic for Cognitive Neurology, University Hospital Leipzig, Germany

BACKGROUND

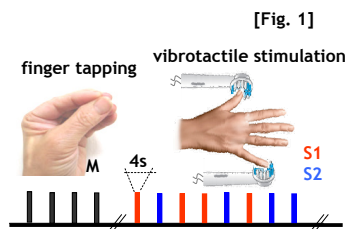
Near-infrared Spectroscopy (NIRS) is a versatile functional imaging tool of great flexibility

- Besides of advantages (interference-free, low cost, portability) a major shortcoming of this methodology is the low spatial resolution
- Improvement of spatial resolution can be obtained by increased probe-density and usage of the multi-distance approach
- Zeff et al. [1] showed retinotopic activations in the human visual cortex to excentric and rotating stimuli by high-density optical tomography.
- Here we investigate whether high-resolution optical topography allows to demonstrate homuncular somatotopic representation in the somatosensory cortex.

METHODS

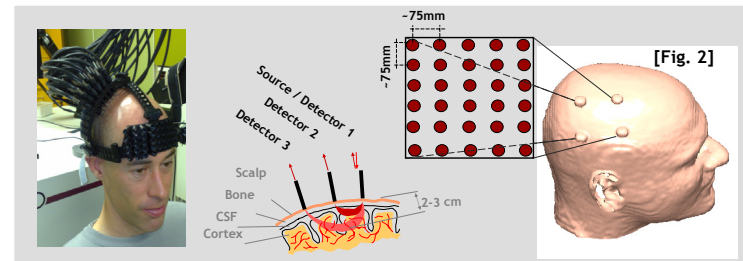
STIMULATION PROCEDURE:

- thumb and the 5th finger of the left hand were stimulated pseudo-randomly with PC-controlled electrical toothbrushes integrated in a glove (8 subjects; 5 male), [Fig. 1]
- 4s vibrotactile stimulation + 12-16s baseline period (on & offsets indicated by tone)
- 20 repetitions for each condition
- subjects also performed randomized self-paced finger tapping to allow localization of sensori-motor cortex (right hand, 4s)
- Task performance was guided by the acoustic sound of the toothbrushes, thus minimizing differences between the somatosensory and the motor task



IMAGING SETUP

- rectangular array of optical probes (30 fibres) were attached over right somatosensory region (C4 according to 10-20 system); [Fig. 2]
- Because each probe is source and detector, the setup provides 900 measuring channels and allows optical tomography (multi distance approach)
- NIRS imaging system: DYNOT 232 (NIRx Medizintechnik GmbH, Berlin, Germany; wl: 760 nm & 830 nm, sf: 2.44 Hz)

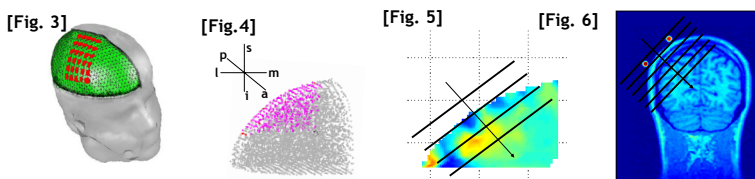


ANATOMICAL MR:

- All subjects had an anatomical MR-scan with fiducial markers

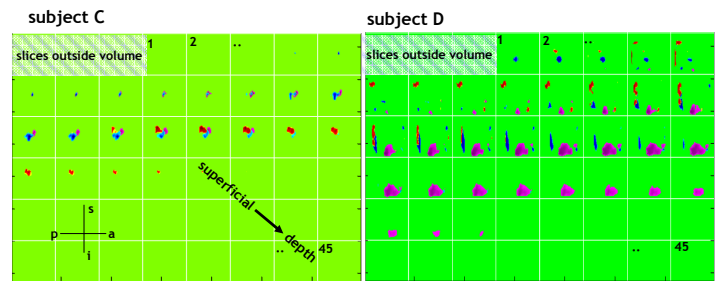
DATA ANALYSIS

- bandpass filtered time series (0.03 Hz to 0.4 Hz) were converted to tomographical hemodynamic changes using NAVI (NIRx N.Y.; FEM model) [Fig. 3]
- GLMs for fingertapping (1 predictor) and somatosensory stimulation (2 predictors) on reduced tomographical data [Fig. 4]
- optical volumes were sliced tangentially to the surface (-45°); [Fig. 5]; this was also done for MR-volume [Fig. 6]

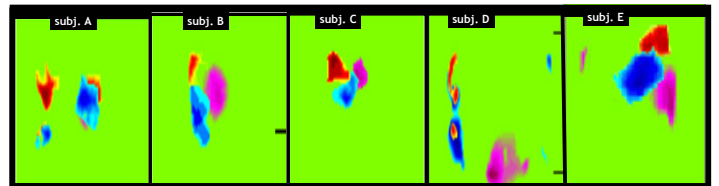


RESULTS

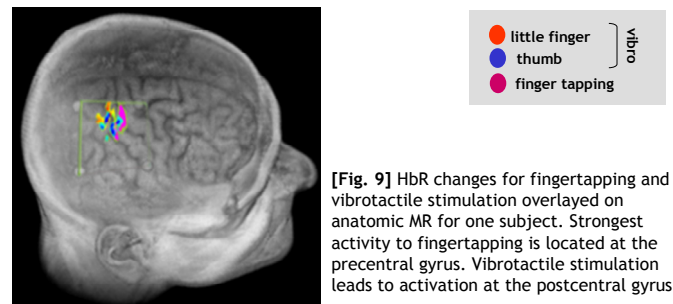
- strongest functional changes to finger-tapping and vibrotactile stimulation at deeper tomographical slices [Fig. 7]
- arbitrary thresholding of T-values reveal distinct 'centers of mass' for fingertapping and vibrotactile stimulation in 6 of 8 subjects [Fig. 8 & Fig 9]:
 - [i] fingertapping leads to a more anterior located activation compared to vibrotactile stimulation and
 - [ii] activation für thumb is more superior located compared to little finger



[Fig. 7] T-values for HbR parameter arbitrary thresholded for each condition from 2 subjects. Panels depict tomographical slices from superficial to deeper slices



[Fig. 8] medium depth (5 subjects): T-values for HbR (arbitrary threshold)



[Fig. 9] HbR changes for fingertapping and vibrotactile stimulation overlaid on anatomic MR for one subject. Strongest activity to fingertapping is located at the precentral gyrus. Vibrotactile stimulation leads to activation at the postcentral gyrus.

DISCUSSION

- The results show that optically based high-density imaging is feasible to localize and discern somatotopic activations to vibrotactile stimulation of different fingers.
- As expected by homuncular organisation of the somatosensory cortex the hemodynamic response to vibrotactile stimulation of the thumb was localized more laterally compared to the 5th finger. This result is in good agreement with fMRI studies that have investigated the human somatosensory system [2,3,4] and prove that functional optical techniques can yield high-resolution maps of functional cortical anatomy.

next steps

- statistical validation of the activation spots for the different conditions
- alignment of functional tomographical data and structural MR

REFERENCES

- References:
- Zeff, B.W., White, B.R., Dehghani, H., Schlaggar, B.L. & Culver, J.P. (2007). 'Retinotopic mapping of adult human visual cortex with high-density diffuse optical tomography', *Proc Natl Acad Sci*, vol. 104, no. 29, pp. 12169-74.
 - Kurth, R., Villringer, K., Mackert, B.M., Schwiemann, J., Braun, J., Curio, G., Villringer, A. & Wolf, K.J. (1998). 'fMRI assessment of somatotopy in human Brodmann area 3b by electrical finger stimulation', *Neuroreport*, vol. 9, no. 2, pp. 207-12.
 - Kurth, R., Villringer, K., Curio, G., Wolf, K.J., Krause, T., Repenthin, J., Schwiemann, J., Deuchert, M. & Villringer A. (2000). 'fMRI shows multiple somatotopic digit representations in human primary somatosensory cortex', *Neuroreport*, vol. 11, no. 7, pp. 1487-91.
 - Ruben, J., Schwiemann, J., Deuchert, M., Meyer, R., Krause, T., Curio, G., Villringer, K., Kurth, R. & Villringer A. (2001). 'Somatotopic organization of human secondary somatosensory cortex', *Cereb Cortex*, vol. 11, no. 5, pp. 463-73.

CONTACT

Stefan P. Koch, Department of Neurology, Charité, Berlin: stefan.koch@charite.de