



Dynamic optical tomography of cerebral vascular hemodynamics

F. X. Castellanos,* A. Di Martino,* H. L. Graber,# Y. Pei,# C. H. Schmitz,# R. L. Barbour#

*Institute for Pediatric Neuroscience, NYU Child Study Center, NYU School of Medicine

Pathology Department, SUNY Downstate Medical Center at Brooklyn

Aim

To examine the feasibility of detecting changes in cerebral blood oxygenation during motor activity using time-series near infrared optical tomography.

Materials and Methods

Instrumentation: A multichannel continuous wave (CW) near infrared (NIR) optical tomographic imager (DYNOT System, NIRx Medical Technologies), operating at wavelengths of 760 nm and 830 nm, allows discrimination between oxyhemoglobin and deoxyhemoglobin concentrations.

Subject: A single right-handed healthy adult female.

Recording: Data were collected from 24 channels in parallel at a source switching rate of 2.5 Hz. 24 source-detector optodes configured in a rectangular pattern (8x6 cm) provided up to 576 independent detector channels. The rectangle was positioned over the left side of the head, approximately overlying the centrotemporal brain area.

Task: After 320 seconds of rest with eyes closed, the subject alternated 3 block periods (~40 sec. each) of right hand four-finger flexion/extension (at 1 Hz) with 3 quiet resting blocks (~40 sec.).

Analysis

Only data from channels with CV < 15% in the baseline time interval were used in subsequent steps.

Data Pre-processing:

1. Low-pass filter (0-0.15 Hz) and normalize the raw detector readings for the two wavelengths.
2. Compute changes in hemoglobin concentration according to the modified Lambert-Beer law from the two wavelengths' time-series data.
3. Perform one-tailed *t*-test comparing motor versus rest, after linear & quadratic detrending.

Image Reconstruction:

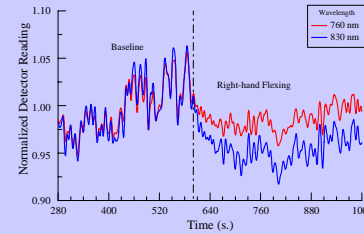
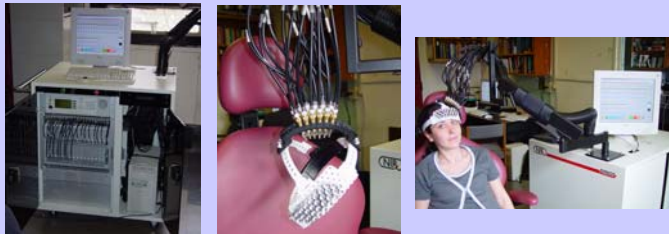
1. Reconstruct images of μ_a (absorption coefficient) for both wavelengths.
2. Algebraically combine μ_a images into spatial maps of the 3 forms of hemoglobin (oxy, deoxy, & total).

Image Post-processing:

1. Select time intervals corresponding to baseline and provocation (Activation/Rest) periods.
2. Compute mean and standard deviation images for each time segment and each hemoglobin form.
3. GLM on data from the two intervals of time selected.

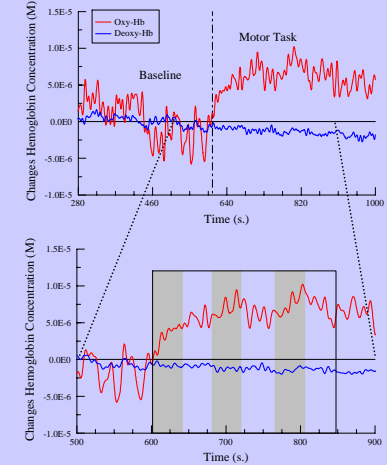
$$\text{model} = c_1 N^{-1/2} + c_2 \left(\frac{t-a_1}{a_2} \right) + c_3 \left[\left(\frac{t-b_1}{b_2} \right)^2 - b_3 \right] + c_4 B(t)$$

GLM code finds the best fit of the time series in each pixel to a model function with the indicated form. N is the number of points in the time interval. $c_1 - c_4$ are the unknown parameters that are solved for. The first three terms are constant, linear and quadratic trend models, and $B(t)$ is the boxcar model function that tracks the task-rest-task-rest-task-rest structure of the Activation/Rest protocol. The quantities a_1, a_2, b_1, b_2, b_3 are not unknown parameters solved for by the GLM code, but are known constants whose function is to normalize the linear and quadratic terms and set their means to zero. All four model functions are normalized to unit sum of squares.



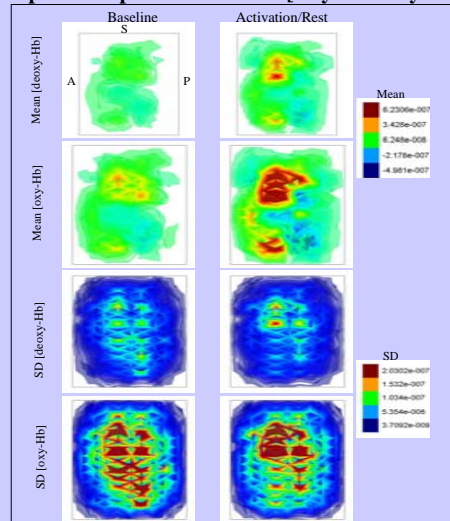
| | [Oxy-Hb] | | [Deoxy-Hb] | |
|----------------|-------------------------|-------------------------|-------------------------|-------------------------|
| | Motor | Rest | Motor | Rest |
| Mean | 1.81x10 ⁻⁷ | -1.76x10 ⁻⁷ | -9.27x10 ⁻⁸ | 8.97x10 ⁻⁸ |
| ±SD | ± 1.16x10 ⁻⁶ | ± 1.25x10 ⁻⁶ | ± 2.68x10 ⁻⁷ | ± 2.65x10 ⁻⁷ |
| <i>t</i> value | 2.16 | | -4.9 | |

Significant [oxy-Hb] increase and [deoxy-Hb] decrease during motor task versus rest in channel 207 (source 9 detector 15). $p < 0.01$.

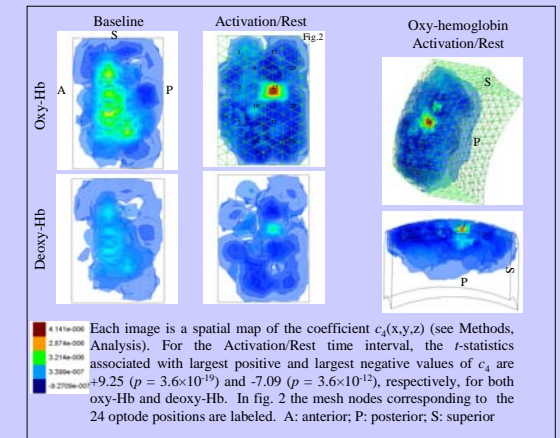


Post-processing: Time-series analysis of reconstructed images

Spatial Maps: Mean & SD - [Oxy & Deoxy-Hb]



General Linear Model



Discussion

- 1) Motor activity was accompanied by a significant increase of [oxyhemoglobin] and significant decrease of [deoxyhemoglobin] in this first subject tested.
- 2) DYNOT can apparently detect expected brain hemodynamic responses provoked by motor activity.
- 3) Planned future studies will assess the test-retest reliability of this signal.
- 4) Despite low spatial resolution, DYNOT may be useful for functional brain imaging in children and adolescents. Studies with dyslexic and nonimpaired pediatric readers are planned.